

# CR

## CASE REPORT

*E. P. C. M. S.*

# A Case of Acute Intermittent Porphyria Complicating Pregnancy

Preetpal Grewal, D.O., PGY-III  
 Claudia Suarez, M.D.  
 Jose Gonzalez, M.D.

*Texas Tech University Health Sciences Center*

### INTRODUCTION AND BACKGROUND

Acute intermittent porphyria is the most common and most severe of the inherited hepatic porphyrias. This condition is an autosomal dominant disorder resulting from a partial deficiency of porphobilinogen deaminase activity, an enzyme in the pathway of heme synthesis [1, 2]. It is also called Swedish porphyria, pyroporphyrria, or intermittent acute porphyria. The estimated prevalence of the disorder is 5-10 case per 100,000 [1, 2]. The usual clinical presentation involves abdominal pain, gastrointestinal symptoms and autonomic nervous system disturbances. These attacks are precipitated by endogenous factors such as drugs, hormones (i.e. estrogens), emotional stress, or starvation states. Pregnancy may precipitate acute attacks of acute intermittent porphyria. When proper precautions are taken, the patient may have an uneventful pregnancy and puerperium. This is a case report of acute intermittent porphyria in pregnancy.

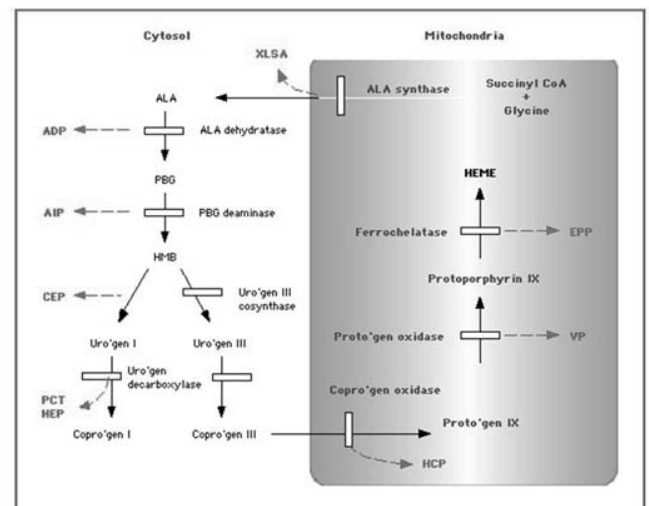
### CASE PRESENTATION

This is a 27 year old G3P2 who began prenatal care in our high risk obstetrics clinic at 23 weeks gestation. She had history of acute intermittent porphyria diagnosed during the previous year. The patient was first admitted to our service with complaints of severe abdominal pain, nausea and several episodes of vomiting. She also complained of pain in her back and legs. She had experienced similar symptoms at 20 weeks gestation. Her history included an admission around 7 weeks gestation for being in a coma. It was at that time she was found to be pregnant. Since her initial admission, the patient had recurrent attacks of abdominal pain and nausea requiring multiple hospital admissions. Her treatment consisted of a high carbohydrate diet of more than 400 gm/day and narcotics for pain control. Additionally, to prevent other attacks, she was advised to avoid prolonged periods of fasting. She incidentally developed mild hypochromic, microcytic anemia that was treated. Her laboratory work up included urine analysis, a glucose tolerance test, and renal function tests, all results were within normal limits. The pregnancy was monitored closely for hypertension and fetal growth and any other symptomatic attacks. The patient delivered a single live born female at 39 weeks with no complications.

### DISCUSSION

The prevalence of acute intermittent porphyria varies in the different areas of the world. Though its association with pregnancy is rare, it presents the obstetricians with challenging problems in diagnosis and management. Porphyria is difficult to diagnose during pregnancy because the symptoms simulate hyperemesis gravidarum or eclampsia. It is thought to be associated with dis-

mal maternal and perinatal outcome. During the acute attack, the neurological dysfunction can involve any portion of the nervous system. An imbalance in the autonomic innervation of the intestine leads to abdominal pain. Peripheral neuropathy such as pain in the back and legs is always preceded by abdominal pain. Other autonomic neuropathies like sweating, vascular spasm, labile hypertension, and sinus tachycardia may occur. More severe symptoms involve the development of respiratory paralysis, central nervous dysfunction along with seizures, coma, hypothalamic dysfunction, and disruptions with cerebellar and basal ganglion function [3]. However, recent reports are more encouraging due to better understanding of the disease process and improved prenatal care [4, 5]. Another pregnancy problem is the use of narcotics to control the acute symptoms and the possibility of opiod withdrawal in the neonate.



**Heme synthesis and the porphyrias** Schematic representation of heme synthesis and the enzymatic defects in the porphyrias, beginning with the formation of ALA from succinyl CoA and glycine. The enzymatic defect in each porphyria is shown by a red broken line. In patients, the substrate for the defective enzyme accumulates and is excreted into urine or stool. ALA = delta-aminolevulinic acid; PBG = porphobilinogen; HMB = hydroxymethylbilane; Uro'gen = uroporphyrinogen; copro'gen = coproporphyrinogen; Proto'gen = protoporphyrinogen; XLSA = X-linked sideroblastic anemia; ADP = ALA dehydratase porphyria; AIP = acute intermittent porphyria; CEP = congenital erythropoietic porphyria; PCT = porphyria cutanea tarda; HEP = hepatoerythropoietic porphyria; HCP = hereditary coproporphyria; VP = variegate porphyria; EPP = erythropoietic protoporphyria.

Continued on page 15

A Case of Acute Intermittent Porphyria Complicating Pregnancy  
(Continued)

Females appear to have more severe symptoms and attacks may be precipitated by menstruation, pregnancy, and oral contraceptive use. Normal pregnancy is associated with urinary excretion of aminolevulinic acid, porphobilinogen, and porphyrins that is 15-60% greater than in non-pregnant females making the diagnosis of acute intermittent porphyria more difficult [4-6]. Pregnant patients with acute intermittent porphyria have higher incidence of acute attacks of porphyria (24-95%), resulting in considerable perinatal mortality (2-42%), high rates of spontaneous abortion (6-12%), hypertension (16%), and low birth weight infants [5]. Patients are instructed to avoid precipitating factors. A high carbohydrate diet (more than 400 gm/day) can decrease porphyrin precursor excretion [4]. For abdominal pain, phenothiazines can be used. Autonomic manifestations such as hypertension and tachycardia can be controlled with the use of propranolol. In patients who do not have coagulopathies, the use of hematin can be considered. Critical monitoring of vitals, intake, output, fluid and electrolyte balance is essential. Porphyrinogenic drugs should be avoided and infections should be treated. All these measures are likely to result in a better pregnancy outcome. The infants should be followed as acute intermittent porphyria is an autosomal dominant condition with variable penetrance.

**REFERENCES**

1. Sassa S. Acute intermittent porphyria. *Up to Date* <http://www.utdol.com/utd/content/>

2. Kanaan C, Veille JC, Lakin M. Pregnancy and acute intermittent porphyria. *Obstet Gynecol Surv* 1989; 44: 244-249.

3. Acute Intermittent Porphyria. <http://medic.uth.tmc.edu/path/00000805.htm>.

4. Aggarwal N, Bagga R, Sawhney H, Suri V, Vasishta K. Pregnancy with acute intermittent porphyria: a case report and review of literature. *J. Obstet and Gynaecol Res.* 2002 June;28(3):160

5. Kantor G, Rolbin SH. Acute intermittent porphyria and Caesarean delivery. *Can J Anaesth.* 1992;39(3):282-5.

6. Olund A. Acute intermittent porphyria complicated by pregnancy. *Clin Exp Obstet Gynecol.* 1988;15:168-9.

---

Preetpal Grewal, D.O., PGY-III, Department of OB/GYN at Texas Tech University Health Sciences Center in El Paso.

Claudia Suarez, M.D., Assistant Professor, Assistant Residency Program Director and Director of the Minimally Invasive Surgical Laboratory in the Department of OB/GYN at Texas Tech University Health Sciences Center in El Paso.

Jose Gonzalez, M.D., Associate Professor, Director of Maternal-Fetal Medicine, Vice-Chair of Clinical Affairs and Residency Program Director in the Department of Obstetrics and Gynecology at Texas Tech University Health Sciences Center in El Paso.