

CR

CASE REPORT

E. P. C. M. S.

Erythema Dyschromicum Perstans (Ashy Dermatitis)

Ruben Ayala, M.D., PGY-2
Lorenzo Aragon, M.D.

CASE REPORT

INTRODUCTION AND SIGNIFICANCE (BACKGROUND)

Erythema Dyschromicum Perstans (EDP) was first described by C. Oswaldo Ramirez of San Salvador, El Salvador, in 1957. He called the patients with this eruption *Los Cenicientos*, meaning the ashen ones. Later, EDP was called dermatosis cenicienta, meaning ashy dermatosis, because of its ashy bluish gray color. [3] In South America, another name, erythema chronicum figuratum melanodermicum, is also used. [1, 3]

The etiology of EDP remains unknown but it has been related to numerous causes such as environmental and chemical exposure, and genetics. [3, 5, 6] HLA-DR association with the genetic susceptibility to develop ashy dermatitis in Mexican Mestizo patients was analyzed, the results of which were reported by Correa in 2007. [1]

SYNONYMS

EDP, ashy dermatosis, dermatosis cenicienta, erythema chronicum figuratum melanodermicum.

CASE PRESENTATION

A 53 y/o Hispanic female was evaluated in our clinic with a history of one year of progressive skin hyperpigmentation, worse in the sun-exposed areas (face and neck) but involving other areas. There were no associated symptoms to these skin changes. Her past medical history was unremarkable. She denied any chemical or environmental exposure. Her vital signs were normal. Physical exam was remarkable for hyperpigmented skin, mostly face and neck.

Work-up involving blood test, abdominal/pelvic ultrasound, and punch skin biopsy at border of lesion was performed. Results were normal, except for her biopsy. Pathology report was consistent with Erythema Dyschromicum Perstans.

DISCUSSION

Erythema dyschromicum perstans has been a very controversial term in the literature. It's a chronic condition characterized by asymptomatic, slate-gray or violaceous hyperpigmented macules, distributed most commonly over the trunk and proximal extremities, and less frequently over the face and neck; as presented by our patient. This case illustrates the importance of recognizing the clinical clues leading to the diagnosis of certain dermatologic diseases basically unseen

in the history and physical examination.

EDP is most common in Latin America and Asia; most of the cases occur in El Salvador where the first case was identified. Cases in Europe have also been described. [3] Both sexes can be affected, but it's more common in women than men. The age range affected is wide. [3, 6]

It's a very rare disorder of pigmentation that is most common in Hispanic patients. Unlike adult patients, children with EDP are usually white. [2, 3, 4] Although the disease is mainly described in patients with dark skin, it has been occasionally described in light-skinned patients. [1, 4] Some authors suggest that the condition is no more than a post-inflammatory pigmentary change in dark-skinned people. [2, 4]

Many therapeutics options are available such as Clofazimine, Dapsone, corticosteroids, antibiotics, antifungals, chemical peels, etc; but few have been effective, and none with satisfactory results, except for Clofazimine. [2, 3, 6]

REFERENCES:

1. Correa MC, Memije EV, Vargas-Alarcón G, Guzmán RA, Rosetti F, Acuña-Alonzo V, Martínez-Rodríguez N, Granados J. Department of Dermatology, Hospital General Manuel Gea Gonzalez, Tlalpan, Mexico. *Journal of the American Academy of Dermatology - Volume 56, Issue 4 (April 2007). HLA-DR association with the genetic susceptibility to develop ashy dermatosis in Mexican Mestizo patients.*
2. Oswald SS, Proffer LH, Sartori CR. Department of Dermatology, Brooke Army Medical Center, San Antonio, Texas, USA. *Cutis.* 2001 Jul; 68(1):25-8. *Links Comment in: Cutis.* 2002 Jul; 70(1):62. *Erythema dyschromicum perstans: a case report and review.*
3. Robert A Schwartz, MD, MPH, Professor and Head of Dermatology, Professor of Medicine, Professor of Pediatrics, Professor of Pathology, Professor of Preventive Medicine and Community Health, UMDNJ-New Jersey Medical School. *Erythema dyschromicum perstans.*
4. Angel Fernández-Flores MD PhD, Manuel G Montero

Continued on page 8

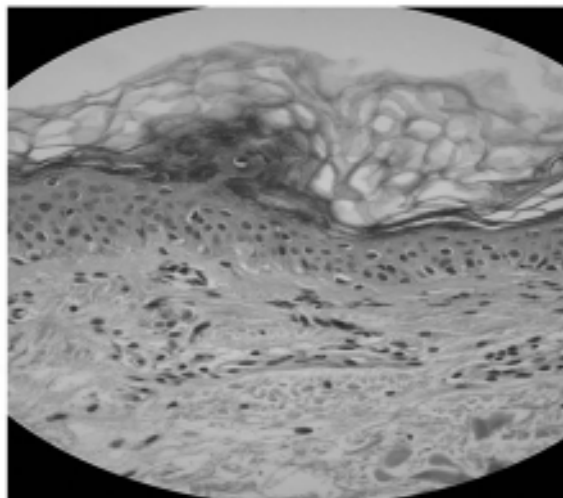
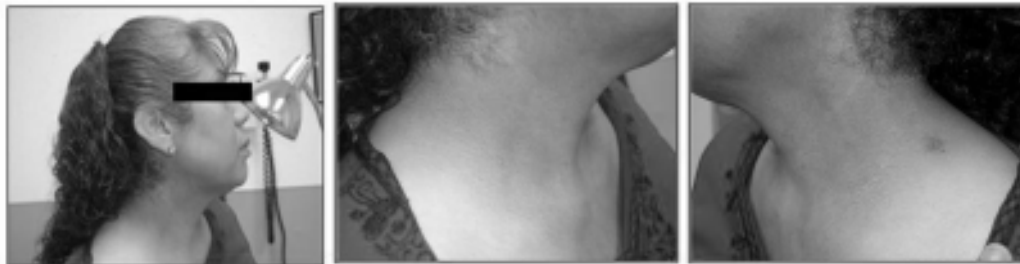
Erythema Dyschromicum Perstans (Ashy Dermatitis)
(Continued)

MD. *Dermatology Online Journal*, volume 12 (number 4): 14. Ashy dermatosis or “Tyndall-effect” dermatosis.

5. Luz, A. Vásquez-Ochoa MD; Diana, M. Isaza-Guzman MSc; Orozco-Mora, Beatriz MD; Restrepo-Molina, Rodrigo MD;

Trujillo-Pérez, Judith BLC; Félix, J. Tapia MPH. *International Journal of Dermatology*. 45(8):937-941, August 2006. Immunopathologic study of erythema dyschromicum perstans (ashy dermatosis).

Patient’s photos and biopsies



Ruben Ayala, M.D., PGY-2, Resident Physician, Texas Tech University Paul L. Foster School of Medicine, Department of Family and Community Medicine, El Paso, Texas.

Lorenzo Aragon, M.D., Assistant Professor, Texas Tech University Paul L. Foster School of Medicine, Department of Family and Community Medicine, El Paso, Texas.