

CR

CASE REPORT

E. P. C. M. S.

Goldenhar Syndrome with a Rare Complication: Hydrocephalus

Jianzhong Ji, M.D., Ph.D., PGY-3

Jyoti Nair, M.D., PGY-2

Kate Flather, M.D., PGY-3

Ralista Akins, M.D., Ph.D.

Fares Kokash, M.D.

TTUHSC Paul L. Foster School of Medicine

BACKGROUND

Goldenhar syndrome, also known as oculo-auriculo-vertebral spectrum (OAV) is a rare disorder in which the facial and vertebral anomalies are frequently associated with cardiac and pulmonary defects. The syndrome was first described by Dr. Maurice Goldenhar in 1952. The abnormalities usually involve one side of the body, and may range from mild to severe. While the deformities of the face, spine and some internal organs are typical, the presence of hydrocephalus is a rare association, which prompted us to report this case (1, 2).

Although Goldenhar Syndrome appears sporadically, in some cases positive family histories have pointed out the possibility for inheritance patterns. In addition, some researchers suggest that the disorder may be caused by gene interactions, possibly in combination with environmental factors, thus supporting a theory of multifactorial inheritance (3, 4).

CASE PRESENTATION

A one-year-old female patient with a known case of Goldenhar syndrome was admitted to the hospital with an MRI of the brain that showed an 87.2 X 84.5 X 40.7 mm extensive cystic lesion in the infra-tentorial space. The cyst produced a severe mass effect with downward protrusion of the cerebellum and cerebellar tonsil in foramen magnum. The patient had knowledge of this cyst since birth, but it had now increased in size. The patient's mother reported no history of irritability, changes in sensorium, difficulties breathing or feeding and no seizures.

The patient was born preterm (34 weeks) by cesarean section due to breech-positioned twins in labor. The mother had prenatal care in Mexico and no abnormalities were detected according to the existing files. One of the twins died at birth with fetal hydrops, and the surviving twin had congenital dysmorphic features in general, respiratory distress and skeletal anomalies resembling arthrogryposis. The anomalies included dislocated hips and arthrogryposis of hands and feet, small shield chest, periauricular skin tags on left cheek and on the tragus, coloboma of the left upper eyelid, and macrostomia of the left lateral commissurae. A CT scan was done of the face at birth and a small arachnoid cyst was diagnosed. In the neonatal period the patient had eye surgery for removal of the left eye cleft.

At admission to the hospital, the patient was 12 month old but could not sit on her own, though she could sit with support. The patient was evaluated by radiologic studies and hydrocephalus was diagnosed. Two days after the admission, she had a

cystoperitoneal shunt with placement of a programmable Codman valve set at 40 mm of pressure without siphon device. Post operatively, a CT of her head showed that the cyst was decreasing in size and the patient was discharged and followed up by neurosurgery.

DISCUSSION

Goldenhar syndrome has variable presentation, most often including hypoplasia of one side of the face, microphthalmia, microtia, reduced maxilla and mandible, pre-auricular skin tags, and existence of hemivertebrae. A number of internal organs (e.g., heart, lungs, kidneys), can also be hypoplastic, most often unilaterally, but bilateral cases have also been described. When the deformities are limited to only one side of the face, and the spine and internal organs manifestations are spared, the condition is called hemifacial microsomia.

Goldenhar's syndrome is a rare disorder. In 1967, there were only about 200 cases diagnosed in the U.S. However, after the Gulf War in 1991 the incidence increased allegedly due to war-related exposure to chemicals (5). The condition affects males more often than females, and its incidence is considered to be approximately 1:5,000 live births.

Although the cause of Goldenhar syndrome is unknown, it has been associated to several causes. The main one is exposure to hazardous chemicals or toxins, such as dioxin. Secondly, patients with hearing loss and Goldenhar syndrome have been associated to maternal infections during pregnancy with CMV or varicella. Last, some authors suggest that the disorder is due to maldevelopment of a brachial arch or a vascular incident during the first trimester, when the face of the embryo is being developed. In addition, the syndrome has been described in several chromosomal rearrangements such as deletion of the terminal 5p.

A possible correlation between Autism Spectrum Disorder (ASD) and oculo-auriculo-vertebral spectrum (OAV) has been described. ASD may be associated with errors in early embryonic brain development. Awareness of the coexistence of OAV/ASD is important in habilitation care of individuals with OAV (6).

Treatment of Goldenhar Syndrome is usually confined to such surgical interventions that may be necessary to allow the child to develop normally e.g. jaw distraction/bone grafts, ocular dermoid debulking, repairing cleft palate/lip, repairing heart mal-

Continued on page 10

formations, spinal surgery. Dependent on the severity of Goldenhar Syndrome, the patient may require multiple surgeries. The facial and vertebral anomalies are frequently associated with cardiac and pulmonary defects and present a difficult technical challenge for proper anaesthetic management. (6).

Children with Goldenhar Syndrome usually have a normal life-span and normal intelligence. In some cases, special care may be needed, including hearing aid, speech therapy, orthodontic treatment, and in severe cases, plastic surgery and physiotherapy may be necessary. Pre-natal scanning may identify the condition in certain cases where facial or skeletal anomalies are present. Pre-natal screening and genetic advice may be offered for future pregnancies.

REFERENCES

1. Hajje MJ, Nachanakian A, Haddad J. Goldenhar syndrome and arachnoid cyst. *Arch Pediatr.* 2003 Apr; 10 (4): 353-4.

2. Kumar R, Balani B, Patwari AK et al. Goldenhar syndrome with rare association. *Indian J Pediatr.* 2000 Mar; 67 (3): 231-3.

3. Touliatou V, Fryssira H, Mavrou A, Kanavakis E, Kitsiou-Tzeli S (2006). "Clinical manifestations in 17 Greek patients with Goldenhar syndrome". *Genet. Couns.* 17 (3): 359-70.

4. M. Goldenhar. Associations malformatives de l'oeil et de l'oreille, en particulier le syndrome dermoïde epibulbaire-appendices auriculaires-fistula auris congenita et ses relations avec la dysostose mandibulo-faciale. *Journal de génétique humaine, Genève, 1952, 1: 243-282.*

5. Araneta MR, Moore CA, Olney RS, et al (1997). "Goldenhar syndrome among infants born in military hospitals to Gulf War veterans". *Teratology* 56 (4): 244-51.

6. J.L. Scholetes, F. Veyckemans, L. Van Obbergh, et al. Neonatal anesthetic management of a patient with Goldenhar's syndrome with Hydrocephalus. *Anesthesia and intensive care, Vol 15. No 3, 1987: 338-40.*

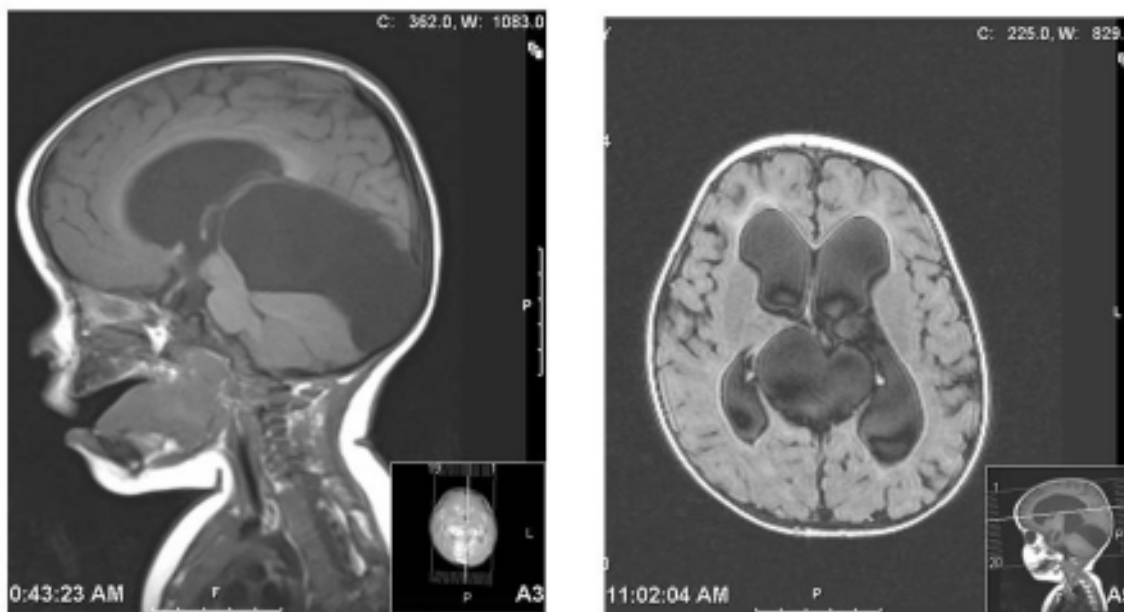


Figure 1 and 2
1 and 2. Posterior fossa arachnoid cyst with transtentorial and cerebellar tonsil herniations, associated with an acute hydrocephaly.

Jianzhong Ji, M.D., Ph.D., PGY-3, Department of Pediatrics, TTUHSC Paul L. Foster School of Medicine, El Paso, Texas.

Jyoti Nair, M.D., PGY-2, Department of Pediatrics, TTUHSC Paul L. Foster School of Medicine, El Paso, Texas.

Kate Flather, M.D., PGY-3, Department of Pediatrics, TTUHSC Paul L. Foster School of Medicine, El Paso, Texas.

Ralitsa Akins, M.D., Ph.D., Associate Program Director, Academic Assistant Professor and Associate Director of Residency Program, Department of Pediatrics, TTUHSC Paul L. Foster School of Medicine, El Paso, Texas.

Fares Kokash, M.D., Associate Professor, Department of Pediatrics, TTUHSC Paul L. Foster School of Medicine, El Paso, Texas.