

CP

CASE PRESENTATION

E. P. C. M. S.

Esophageal Leiomyoma

Anne T. Saladyga, CPT, MC
Sukhyung H. Lee, CPT, MC
Jason M. Johnson, MAJ, MC

A 28 year old female presented to the emergency department with a three day history of intermittent, substernal chest pain, worse when supine. She also described dysphasia without nausea or vomiting. Chest x-ray (Figure 1) showed opacification of right inferior lung field and chest CT (Figure 2) revealed a 15.7cm x 11.1cm posterior mediastinal mass filling the right posterior thorax. EGD and bronchoscopy confirmed no mucosal connection between the mass and mediastinal structures. Pulmonary function tests showed preserved lung volume and a decreased FEV1 to 80%. Preoperative biopsy was not performed.

The patient initially underwent right sided video assisted thorascopy, which was converted to a right posterolateral thoracotomy due to the size of the mass (Figure 3). The tumor was connected to the esophageal muscularis propria through filmy attachments and tributary vessels, which were bluntly dissected and ligated. There was no violation of esophageal mucosa and the muscularis was approximated over a bougie. The patient was released from the hospital eight days later. The specimen weighed 1.63kgs. Pathology showed a leiomyoma: benign spindle cells arranged in bundles and fascicles with alternating parallel and cross section in a herringbone pattern, typical of a smooth muscle neoplasm (Figure 4).

Esophageal leiomyomas are rare smooth muscle tumors of the esophagus. They rarely grow larger than 5cm or cause symptoms such as chest pain, pressure, and dysphagia.¹ Evaluation for intraluminal esophageal connections or malignant characteristics are necessary, and may consist of barium swallow, endoscopy, endoscopic ultrasound, or CT scan.¹ Endoscopic biopsy is contraindicated, as it increases the risk of rupture, hemorrhage, infection, or mucosal tear at time of surgical resection. Surgical enucleation via VATS or open thoracotomy is preferred treatment for symptomatic patients, although esophageal resection is required in up to 10% of patients.^{1,2} Esophageal myotomy should be repaired, since diverticula can lead to dysphagia.^{1,2} If primary repair cannot be performed due to risk of stricture, a tissue flap is used.¹

REFERENCES

1. Lee LS, Singhal S, Brinster CJ, Marshall B, Kochman ML, Kaiser LR, Kucharczuk JC. Current management of esophageal leiomyoma. [Review] [64 refs] [Journal Article. Review] *Journal of the American College of Surgeons*. 198(1):136-46, 2004 Jan. UI: 14698321
2. Mutrie CJ, Donahue DM, Wain JC, Wright CD, Gaissert HA, Grillo HC, Mathisen DJ, Allan JS. Esophageal leiomyoma: a 40-year experience. [Journal Article] *Annals of Thoracic Surgery*. 79(4):1122-5, 2005 Apr. UI: 15797036

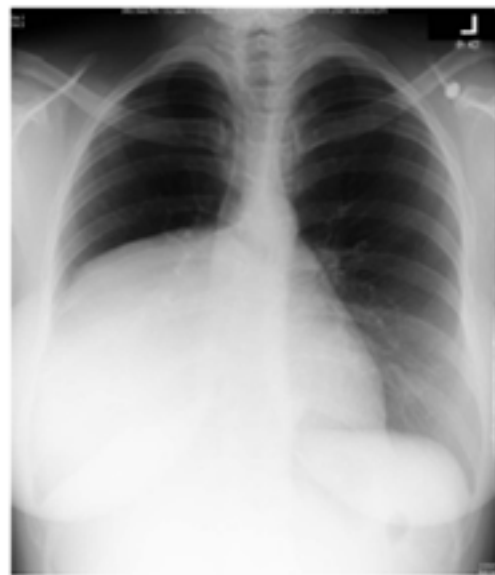

Figure 1: Initial chest x-ray

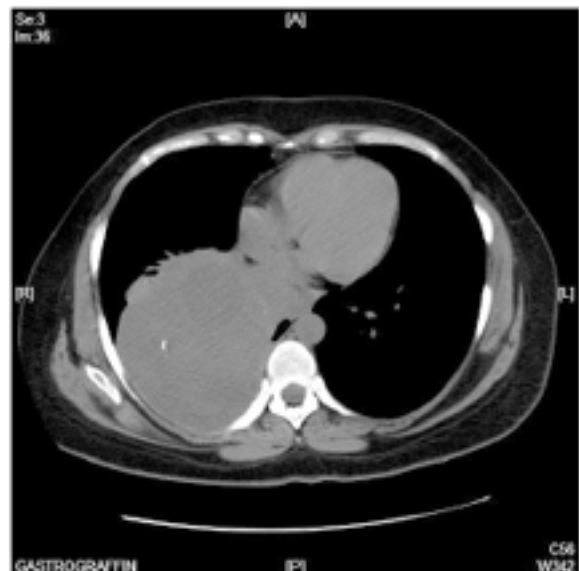

Figure 2: Preoperative CT scan

Continued on page 10

Esophageal Leiomyoma
(Continued)




Figure 3: View of mass through right thoracotomy

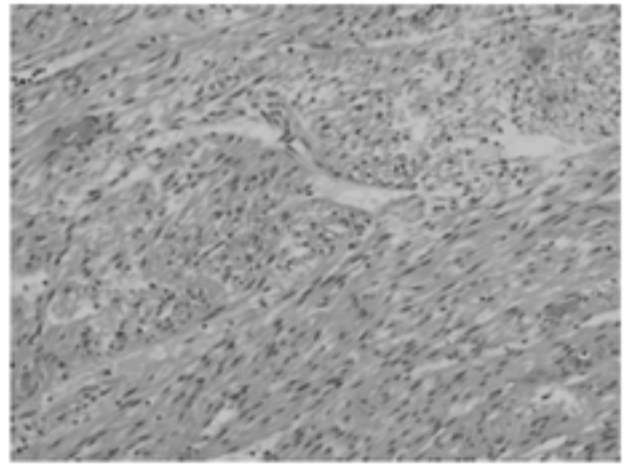


Figure 4: Final pathology hematoxylin and eosin slides

Anne T. Saladyga, CPT, MC, William Beaumont Army Medical Center, El Paso, Texas.

Sukhyung H. Lee, CPT, MC, William Beaumont Army Medical Center, El Paso, Texas.

Jason M. Johnson, MAJ, MC, William Beaumont Army Medical Center, El Paso, Texas.

